

# MicroPulse™ Laser Therapy Eliminates the Need for Further Treatment of DME Patient



**Elias Reichel, MD**, specializes in medical and surgical treatment of vitreoretinal disease. He is Professor and Vice Chair for Research and Education in the Department of Ophthalmology and Director of the Vitreoretinal Diseases and Surgery Service at the Tufts University School of Medicine's New England Eye Center in Boston.

For quite some time I've followed the literature on MicroPulse Laser Therapy, which has shown it to be tissue-sparing to the point of allowing treatment through the fovea. This year, I started using it in my practice in patients with diabetic macular edema (DME) and patients with central serous retinopathy. Many of my MicroPulse patients are early in their treatment course for DME (I've avoided treating eyes with chronic disease). In approximately 50% of these cases, I'm seeing a treatment effect and have been pleased with the early outcomes. In the case I describe here, the patient had an incomplete response to an initial subthreshold conventional laser treatment, but has not required further treatment since one application of MicroPulse.

## PATIENT PRESENTATION AND INITIAL TREATMENT

This 64-year-old male diabetic patient first required treatment for DME in his right eye at his Oct. 9, 2013 visit. On that day, slit lamp examination revealed clinically significant macular edema involving the center of the fovea. (Figure 1) Central retinal thickness (CRT) as measured by spectral-domain OCT was 413  $\mu\text{m}$ , and visual acuity was 20/40. I performed a modified focal/grid laser treatment, using a conventional green laser at subthreshold settings.

## TREATMENT WITH MICROPULSE LASER THERAPY

The patient returned for follow-up on Feb. 12, 2014. The green laser subthreshold treatment he received in his right eye at his previous visit resulted in a decrease in CRT, from 413  $\mu\text{m}$  to 336  $\mu\text{m}$ , and accompanying improvement on the OCT topographic map. (Figure 2) However, the macular edema had not resolved completely. To address the remaining edema, I performed MicroPulse with the IRIDEX IQ 577 $\text{\AA}$  (yellow) laser. (Table 1) Rather than titrate the treatment settings by performing a test application with

***"I also used the TxCell Scanning Laser Delivery System, which improves the consistency of high-density spot placement and saves time compared with single-spot delivery."***

the laser in continuous-wave mode, I used the standard parameters reported in the literature by researchers and experienced MicroPulse users. This patient is very lightly pigmented, so I used 400 mW of power. The other parameters were set as follows: 200- $\mu\text{m}$  spot size, 200-ms exposure duration, 5% duty cycle. Aided by a Reichel-Mainster contact lens, I applied the treatment to all areas of retinal thickening, including through the fovea. I also used the TxCell $\text{\AA}$  Scanning Laser Delivery System, which

## A WELCOME ADDITION TO THE PRACTICE

My experience with MicroPulse so far has been positive. In my hands, it has been very successful in cases that involve minimal to moderate amounts of intraretinal or subretinal fluid (approximately 400  $\mu\text{m}$  or less). When retinal thickening approaches or exceeds 450  $\mu\text{m}$ , I have found it useful to provide pharmacological treatment before proceeding with MicroPulse. In the majority of my DME cases, laser is a reasonable treatment option, and the gentle yet effective performance of MicroPulse likely gives it an advantage over other laser modalities. In addition, I appreciate the opportunity to use non-invasive treatments, especially for the diabetic eye.

The IRIDEX IQ 577 laser can be used for MicroPulse in addition to single spot and multispot continuous-wave treatments, which makes it a cost-effective, space-friendly and efficient device. Two of the features I appreciate are the abilities to store preset treatment parameters for easy access and to switch between continuous-wave and MicroPulse modes with the touch screen display.

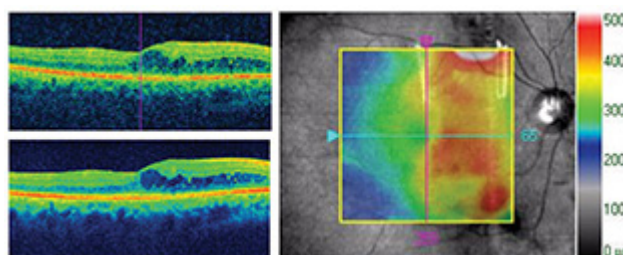


Fig 2. Feb. 12, 2014 | right eye | post conventional laser treatment, prior to MicroPulse | CRT 336  $\mu\text{m}$  | VA 20/40.

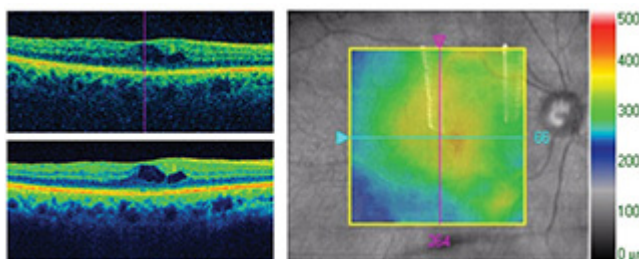


Fig 3. July 16, 2014 | right eye | 5 months post MicroPulse CRT 356  $\mu\text{m}$  with further improvement indicated on OCT topographic map | VA 20/40

improves the consistency of high-density spot placement and saves time compared with single-spot delivery. In fact, it's virtually impossible to create confluent, grid patterns without TxCell.

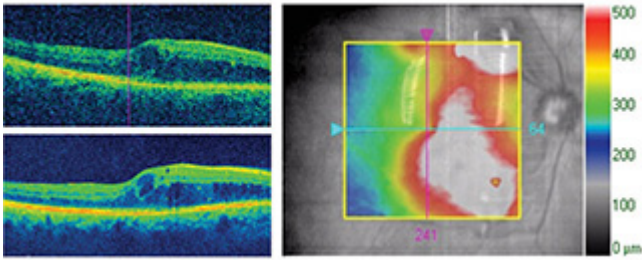


Fig 1. Oct. 9, 2013 | right eye | prior to conventional laser treatment  
CRT 413 Åm | VA 20/40.

While TxCell makes spot delivery more predictable and efficient, I find it useful to note an anatomical landmark at the outset in case the patient or I move during the procedure. As is typically the case, the treatment was not difficult for this patient, and we encountered no problems.

The patient's MicroPulse follow-up visit was July 16, 2014. By that time, 5 months after the treatment, the macular edema in his right eye was largely resolved. (Figure 3) The measured CRT was 356 Åm; however, the reduction in retinal thickness that had occurred since his initial visit was clear on the OCT topographic map. His visual acuity was maintained at 20/40. We scheduled him for a follow-up visit in a few months. If at that time his macular edema returns, I will re-treat with MicroPulse given his initial response.

## Table 1. TREATMENT PARAMETERS

IQ 577 with TxCell-guided MicroPulse for DME

- Wavelength: 577 nm
- Spot size on slit lamp adapter: 200 µm
- Contact lens: Reichel-Mainster
- Power: 400 mW
- Exposure duration: 200 ms
- Duty cycle: 5%
- TxCell-guided MicroPulse Delivery: High-density application of 147 total spots delivered confluent (zero spacing) in three 7x7 treatment grids to all areas of retinal thickening, including over the fovea.

To learn more about MicroPulse, go to  
[www.iredex.com/micropulse](http://www.iredex.com/micropulse)